



**PATIENT**

Freddie Cerreta

**SPECIES**

Canine

**BREED**

Chihuahua mix

**SEX**

Male Neutered

**AGE**

13 years

**WEIGHT**

7.38lbs

**INTERPRETED BY**

Maggie Machen  
Lamy, DVM  
DACVIM (Cardiology)

**IMAGING PERFORMED BY**

Pamela Harrigan,  
RDCS

**HOSPITAL NAME**

Mass Veterinary Services

**REFERRING VET**

Dr. Masloski

**INVOICE**

29737

**DATE**

3/21/23

**PRESENTING CLINICAL SIGNS**

History: Freddie is referred to evaluate a heart murmur. Also, history of seizure activity starting approximately 2 years ago. The seizures have increased in frequency from every few months to every ~ 3 weeks. Freddie has also been coughing a great deal, but the cough has gotten better since starting Pimobendan. He has a good appetite and normal activity level. On exam: NSR, grade IV/VI murmur with PMI left apical area radiating to right, PSS, lung fields clear, mm pink, moist, CRT<2. BP: 90mmHg x 5. \*Sedated with propofol for exam 1) Pimobendan/vetmedin 1.25mg 1 tab am with 1/2-tab pm.

**ECHOCARDIOGRAM FINDINGS**

2D, m-mode, color flow and Doppler imaging is available.

**Left ventricle:** The LV diameter is borderline increased with hyperdynamic function. LV wall thicknesses are normal.

**Left atrium:** The left atrium is moderately dilated.

**Mitral valve:** The mitral valve is diffusely thickened with mild prolapse into the left atrial lumen. Moderate eccentric mitral regurgitation with a normal velocity.

**Aortic valve/Aorta:** The aortic valve is normal in morphology and mobility. Normal aortic outflow velocity; laminar flow. No aortic insufficiency.

**Right ventricle:** Normal right ventricular diameter and morphology indicating no overt evidence of pulmonary arterial hypertension.

**Right atrium:** Normal RA dimension.

**Tricuspid valve:** The tricuspid valve appears mildly thickened with mild tricuspid regurgitation. Normal velocity.

**Pulmonic valve/Pulmonary artery:** The pulmonic valve is normal in morphology and mobility. No pulmonic insufficiency. Normal RVOT velocity; laminar flow.

**Pericardium/other:** No pericardial or pleural effusion noted. No obvious cardiac masses.

**Heart rhythm:** ECG reveals a sinus rhythm with an average HR of 150bpm.

**2-Dimensional Measurements**

Ao diam (cm)	1.2
LA diam (cm)	2.1
LA:Ao (Swe)	1.8
IVS thickness (cm)	0.6
LVID diastole (cm)	2.2
PW thickness (cm)	0.7
LVID systole (cm)	1.1
FS (%)	50

**Doppler Measurements**

PV Vmax (m/s)	0.6
AoV Vmax (m/s)	0.93
MR Vmax (m/s)	4.8
TR Vmax (m/s)	2.3
TR PG (mmHg)	21

**INTERPRETATION OF THE FINDINGS**

Chronic degenerative valve disease causing moderate mitral and trace tricuspid regurgitation. Moderate left atrial enlargement indicates there is relatively low risk for imminent complication, however risk for progression to spontaneous congestive heart failure in the future is elevated. No additional issues are identified.

Given these findings, continue Pimobendan as prescribed. Assessment of progression in the future will help predict long term outcome, however prognosis is guarded at this stage (B2).



**PATIENT**  
Freddie Cerreta

The cough is suspected to be due to a combination of mainstem bronchi compression and potentially airway disease in this predisposed breed. Screening CXR, hydrocodone, etc. may be useful.

**SPECIES**  
Canine

**RECOMMENDATIONS**

- Continue Pimobendan 0.3mg/kg PO q12h.
- Consider CXR, hydrocodone, etc. as discussed.
- Omega fatty acid supplementation and mild salt restriction may be of some long-term benefit.
- Anesthetic risk is considered mild if needed. Cardiac protective drug choices (opioid/benzodiazepine premedication, propofol or alfaxalone induction, isoflurane gas) are recommended. Pre-oxygenate for 5-10 minutes prior to induction. Monitor for arrhythmias, hypotension, and hypoxia both intra and post-operatively and intervene as necessary. Mild IV fluid restriction is recommended to avoid fluid overload. Avoid heart rate stimulating drugs such as atropine unless clinically indicated.
- Monitor for development of a cough, labored breathing, exercise intolerance or collapse episodes.

**BREED**  
Chihuahua mix

**SEX**  
Male Neutered

**AGE**  
13 years

**WEIGHT**  
7.38lbs

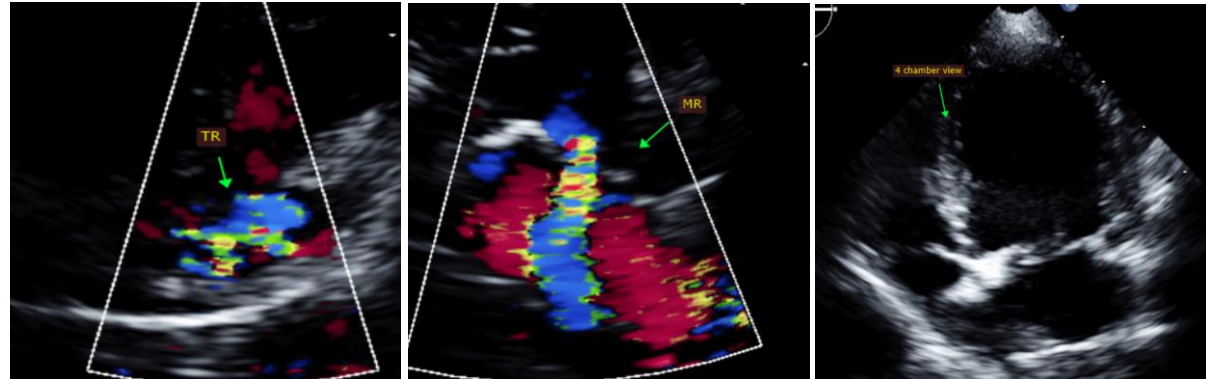
**PLAN**

- Recommend conservative monitoring with a recheck echocardiogram in 6 months, sooner if any development of clinical signs.

**IMAGES**

**INTERPRETED BY**

Maggie Machen Lamy, DVM  
DACVIM (Cardiology)



**IMAGING PERFORMED BY**

Pamela Harrigan, RDCS

**HOSPITAL NAME**

Mass Veterinary Services

The information and recommendations provided are based on the images presented by the referring veterinarian. No evaluation can be communicated regarding pathology that was not visible in the image/video clips provided.

**REFERRING VET**

Dr. Masloski

Thank you for this referral. This report was generated using transcription software, and minor dictation errors may be present. If the clinical or image interpretation does not parallel your findings or if I can be of any further assistance, please contact me.

**INVOICE**  
29737

Maggie Machen Lamy, DVM  
Diplomate of the American College of Veterinary Internal Medicine (Cardiology)  
info@sonopath.com

**DATE**  
3/21/23

Echocardiogram performed by: Pamela Harrigan, RDCS  
Pet Animal Ultrasound Service (4paus.com)